

**Case Report****Fronto-ethmoid Schwannoma “Unusual presentation of Rare Sinonasal Tumor”**

Zuhera Khan, Akbar Abbas

**Abstract:** Epiphora or excessive tearing is usually caused by local eye infection like conjunctivitis, corneal ulcers, trichiasis or ectropion of lid or due to atresia of nasolacrimal ducts in infants. It is case of 32 year old Asian male with no significant social or physiological comorbid has presented with progressive history excessive tearing for 2 years, his symptoms began in Dubai for which he consulted Ophthalmologists who treated him for local causes of epiphora but his symptoms persisted, after two years he had a CT which revealed a mass in frontoethmoidal sinus, a nasendoscopy and excision planned but failed because of excessive bleeding and difficulty in negotiating scope beyond the mass but a piece of mass taken out for histopathology which revealed benign but rare sinonasaltumor “schwannoma.” MRI done for better visualization and extent of mass. Open resection performed. Patient is free of symptoms.

**Keywords:** epiphora, fronto-ethmoid sinus, sinonasalschwannoma.’

*How to cite this: K Zuehra, A Akbar. Fronto-ethmoid Schwannoma “Unusual presentation of Rare Sinonasal Tumor” JIMC 2021; 3.(2):228-230*

**Correspondence**

Dr. Zuhera Khan  
FCPS Plastic Surgery  
Assistant professor Indus Medical College,  
TMK  
Pakistan  
**Email:** drzuherakhan@gmail.com

**INTRODUCTION**

Schwannomas are benign tumors of peripheral nerve sheaths they develop when Schwann cells grow abnormally. The head and neck region is most common site for schwannoma approximately 25 to 45% of all cases<sup>1</sup>. Most common head and neck schwannoma are acoustic neuroma which occurs as part of syndrome called neurofibromatosis. But they can develop anywhere in peripheral nerve sheaths. However only 4% of head and neck schwannomas involve sinonasaltract.<sup>1</sup> the ethmoidal sinus is most frequently involved; maxillary sinus, nasal fossa, and sphenoid sinus are others respectively. Frontal sinus involvement is extremely rare, and there are only a few reported cases.<sup>1</sup> the involvement of nasal cavity and paranasal sinus is rare and rarely extends intracranially or intraorbitally<sup>2</sup>. Signs and symptoms of schwannomas depends on location of tumor, in nasal cavity and paranasal sinus it may present as nasal blockage, rhinorrhea, headache, epiphora and epistaxis often recurrent.

**Case report:**

32 year old male with no known co-morbid presented with progressive history excessive tearing for 2 years, his symptoms began in Dubai where he described an initial period of excessive tearing at certain period of day time but later it progressed to happen throughout the day, he ignored it for couple of months but when severity of tearing has increase

he sought medical advice and consulted an ophthalmologist who advised him few topical medication for conjunctivitis, he used those eye drops and felt some relief but after one month he again had same problem and now situation was more worse so he consulted another ophthalmologist who treated him on same line in Dubai, but when tearing was not getting better patient had been referred to ENT specialist who had his CT of paranasal Sinus which showed blockage of right side of nasal cavity and likely causes pointed out to crusting or polyp or tumor. On examination he had Epiphora and his right eye had proptosis. He had no history of recent headaches, anosmia or recent change in behavior, visual disturbance or blackouts. Other features of his history were unremarkable.

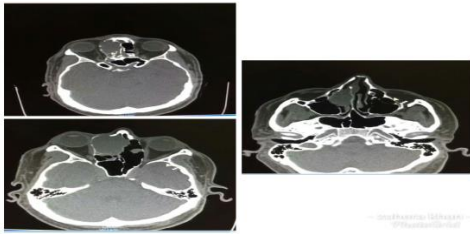
**INVESTIGATION**

A high-resolution CT scan of nose and paranasal sinuses showed hyperdensity of right frontal, ethmoidal maxillary and sphenoidal sinuses and right nasal cavity. The mass has significantly displaced the septum and lateral nasal wall to orbit, causing marked effacement. C shaped septal deformity also present.

Fig:1. Image in left up corner: CT Axial view shows isodense mass filling right nasal cavity, lateral nasal wall bulging into orbit. opacification with loss of aeration seen in right ethmoidal sinus, it's also expanded causing remodeling of lamina papyracea in addition to break in lamina papyracea, indenting the medial rectus muscle on right side as well as mild displacement of right eye globe towards temporal side. See(image in left lower corner: CT axial view, showed marked bulging of right nose and mass abutting the medial wall of orbit with mild proptosis of right eye with deviated nasal septum. Mass is

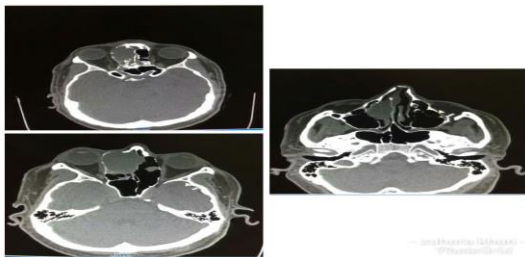
sabutting the medial rectus without extension into the right orbital cavity.

**Fig.1:** Retrobulbar fat planes intact. See (image on right side: Ct axial view shows a soft tissue opacification into right maxillary sinus anteriorly with erosion of medial wall of maxillary sinus.

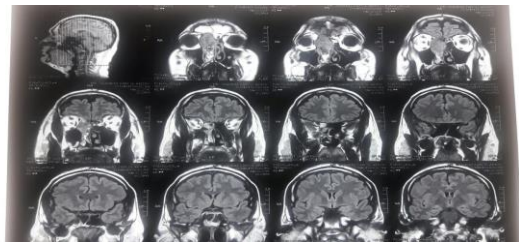


**Fig.2:** CT scan" coronal views: shows an opacification in right Ethmoid and frontal sinus. Mass is abutting the medial wall of orbit having mass effects of medial rectus and displacing eye ball laterally. Mass is also abutting septum to opposite side. With complete obstruction of right nasal cavity. Erosion of medial wall of maxillary sinus is also noted.

MRI scan performed for better visualization of mass.



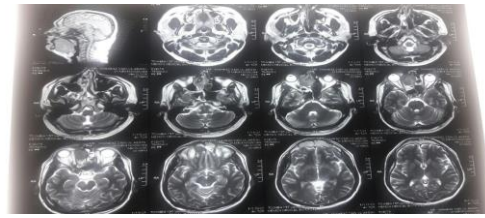
**Fig: 3:** MRI T1 weighted image in coronal view shows mass in right ethmoid region abutting medial wall of orbit without invasion of orbital cavity



**Fig: 4:** MRI coronal view, Mass pushing right orbital contents laterally with no radiological invasion of orbital and cranial cavity. Nasendoscopy examination couldn't be done because of complete blockage of nasal cavity in Dubai. Later patient had been referred to consult doctor in Pakistan with his CT report. Biopsy of tumor performed under General Anesthesia, while taking out biopsy patient bled a lot and after taking piece of tissue for histopathology nasal cavity packed and MRI planned. MRI of nose and paranasal sinuses performed meanwhile biopsy report of tumor received which showed Schwannoma. Keeping the rarity of disease and its

atypical presentation case had been discussed in MDT for further management.

### TREATMENT



Tumor resection planned in MDT and Neurosurgery team was also involved for resection of intracranial portion of schwannoma. Procedure performed under general anesthesia and Open resection of schwannoma done. Approached through lateral Rhinotomy with modified weber Ferguson with frontal sinus extension incision, both sinuses opened, and tumor excised, lamina papyracea found intact. Highly vascular soft lobulated lesion excised, and tissue sent for histopathology. Grossly specimen was from frontal and ethmoidal sinus, it consists of multiple tan brown irregular tissues measuring 5x3.5x1.5cm. Sections reveal polypoidal tissue fragments lines with respiratory epithelium admixed with fragments of neoplastic lesion. The polypoidal tissue fragments show focal areas of necrosis with surrounding abscess formation. The fascicles of spindle shaped cells having elongated pointed nuclei with inconspicuous nucleoli coarse chromatin and moderate eosinophilia cytoplasm. Consistent with ethmoidal and frontal schwannoma, which demonstrated strongly positive immunohistochemical staining for S-100, although negative for Cytokeratin AE1/AE3,EMA, Desmin, ASMA, CD34,SOX-10. Immediate postoperative period was uneventful.

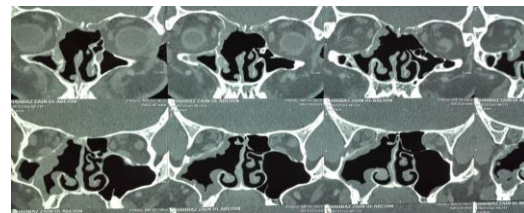
### follow-up

on six-month patient is doing well with no recurrence of symptoms.

Patient is disease free at 2 years follow up.

Follow up CT scan performed at 2 months interval which shows no signs of residual disease.

**Fig: 5.** CT coronal view: Post-surgical scan shows, with loss of opacification and expansion and an air density replacing soft tissue mass, no pressure effects seen on right lamina papyracea.



### DISCUSSION

Epiphora as presentation of schwannoma is very rare. Common causes of epiphora are either

overproduction of tears or decreased drainage of tears, resulting in tearing. This can be due to trichiasis and ectropion or nasal obstruction due to polyp or in elderly or in infants because of atresia of nasolacrimal duct. nasolacrimal duct system malformation or trauma to nasolacrimal ducts (iatrogenic or acquired) such as naso-ethmoid region fractures (le fort I maxillary fractures) can also cause epiphora. While head and neck is the most common location of schwannomas, the data regarding these tumors in other locations are relatively sparse<sup>5,7,8,9,10,11</sup>. Schwannoma of sinonasal tract are infrequent, accounting less than 4% of schwannomas of the head and neck. The precise origin of a solitary frontal schwannoma is uncertain, as there are many nerves in the region. The lesion may have arisen from any one of the following nerves: (1) General sensory branches of the ophthalmic division of the trigeminal nerve, either from the anterior ethmoidal branch of the nasociliary nerve or the supraorbital or supratrochlear branches of the frontal nerve (2) Parasympathetic fibers carried by branches of the lateral posterior superior nasal nerves (3) Sympathetic fibers carried by branches of the lateral posterior superior nasal nerves<sup>1,12</sup>. schwannoma of nasal cavity may present worsening or intractable nasal obstruction with pain, headache and epistaxis but can occasionally present as ptosis,

#### References:

- Mangubat EZ, Pitelka L, Petruzzelli GJ, Byrne RW. Frontal sinus schwannoma: case report and review of literature. Skull base reports. 2011 May;1(01):017-22.
- Ulu EM, Çakmak Ö, Dönmez FY, Büyüklü F, Çevik B, Akdoğan V, Coşkun M. Sinonasalschwannoma of the middle turbinate. Diagn Interv Radiol. 2010 Jun 1;16(2):129-31.
- Wong E, Kong J, Oh L, Cox D, Forer M. Giant Primary Schwannoma of the Left Nasal Cavity and Ethmoid Sinus. Case reports in otolaryngology. 2016 Jun 9;2016.
- Siqueira Mario G., Jennings Erik, Moraes Osmar J.S., Santos Marco Tulio S., Zanon Nelci, Mattos Belmiro J. et al . Nasoethmoidschwannoma with intracranial extension: case report. Arq. Neuro-Psiquiatr. [Internet]. 2001 June;59( 2B ): 421-423.
- Butler RT, Patel RM, McHugh JB. Head and neck schwannomas: 20-year experience of a single institution excluding cutaneous and acoustic sites. Head and neck pathology. 2016 Sep 1;10(3):286-91.
- Fujiyoshi F, Kajiyama Y, Nakajo M. CT and MR imaging of nasoethmoidschwannoma with intracranial extension. AJR. Am J Roentgenol. 1997 Dec;169(6):1754.
- J Neurol Surg Rep. 2014 Aug;75(01):e144-8.

#### Authors

- Dr. Zuhera Khan  
FCPS Plastic Surgery  
Assistant professor Indus Medical College, TMK  
Pakistan
- Dr. Akbar Abbas FCPS otolaryngology  
Former Head of the dept ENT and Head and neck cancer dept  
Patel Hospital/ present Assistant Professor Aga Khan university Hospital  
Karachi

#### Authors Contribution

<b>Zuhera Khan</b>	Acquisition of data and reviewed the manuscript
<b>Akbar Abbas</b>	Conception of manuscript writing

proptosis or diplopia<sup>3</sup> and very rarely with epiphora as only complaint as in this case. Mostly schwannomas are focal encapsulated lesions can be removed endoscopically but, in few cases, endoscopic resection isn't possible<sup>11</sup>. The diagnosis of sinonasalschwannoma remains challenging and sometimes, clinical behavior and modern imaging can be misleading.

#### CONCLUSION

Schwannoma is rare, but it has to be added in differential diagnosis of causes of nasal blockage and excessive tearing cases.

#### Recommendation:

As health professional, I would recommend all general physicians to have good knowledge of common ENT problems which would make referral easy and would provide patient care at best.

\*\*\*“The author(s) declare(s) that there is no conflict of interest regarding the publication of this article.” Publication of this case report is purely academic to help other health professionals diagnosing and treating such rare diseases.

**Conflict of interest:** None.

**Funding Source:** None.

- Hong CS, Pomeraniec IJ, Starke RM, Shaffrey ME. Nasoethmoidschwannoma with intracranial extension. Case report and review of the literature. Br J Neurosurg. 2016 Dec 5:1-2.
- Yu E, Mikulis D, Nag S. CT and MR imaging findings in sinonasalschwannoma. AJNR Am J Neuroradiol. 2006 Apr 1;27(4):929-30.
- Buob D, Wacrenier A, Chevalier D, Aubert S, Quinchon JF, Gosselin B, Leroy X. Schwannoma of the sinonasal tract: a clinicopathologic and immunohistochemical study of 5 cases. Arch Pathol Lab Med. 2003 Sep;127(9):1196-9.
- Gupta R, Khurana N, Singh D, Singh S. Schwannoma of nasal cavity with intracranial extension: A rare but interesting phenomenon in a benign neoplasm. Indian J. Pathol. Microbiol. 2008 Jul 1;51(3):447-.
- Adam SI, Vining EM. Endoscopic resection of an anterior skull-base Schwannoma. In International forum of allergy & rhinology 2012 May (Vol. 2, No. 3, pp. 264-268). Hoboken: Wiley Subscription Services, Inc., A Wiley Company.
- Gencarelli J, Rourke R, Ross T, Gravel DH, Purgina B, Jordan D, Agbi C, Kilty SJ. Atypical Presentation of Sinonasal Cellular Schwannoma: A Nonsolitary Mass with Osseous, Orbital, and Intracranial Invasion.

Received Date: 17-Sept-2021  
Accepted Date: 6-Nov-2021